

FOUR-CORNER ARTHRODESIS USING THE QUAD MEMORY STAPLE

E. A. VAN AMERONGEN and A. H. SCHURMAN

From the Department of Plastic and Reconstructive and Hand Surgery, University of Utrecht, Utrecht, The Netherlands

Range of motion, pain, consolidation and complications were evaluated for nine patients who underwent four-corner arthrodesis using the Quad Memory Staple (QMS) at a mean follow-up of 44 months. The mean pre-operative range of motion was 50° extension, 62° flexion, 9° radial deviation and 24° ulnar deviation. The postoperative range of motion was similar to previous studies at 32° extension, 31° flexion, 15° radial deviation and 20° ulnar deviation. The grip strength was 28 kg pre-operatively and 26 kg postoperatively. The mean pain score improved from 41 to 23 and the Disabilities of Arm, Shoulder, and Hand (DASH) score from 24 to 20. Non-union, haematoma and wound infection were not seen and eventually all four-corner fusions were consolidated. The main advantages of the QMS are its compressive property and the simple fixation technique. It gives good stability, enables early rehabilitation and avoids the risks of pin fixation methods.

Keywords: memory staple, four-corner arthrodesis, SLAC wrist, SNAC wrist

Four-corner arthrodesis combines scaphoidectomy with arthrodesis of the capitate, lunate, hamate and triquetrum. Several methods of fixation have been described, including multiple headless screws, circular plates, K-wires and conventional staples (Ashmead et al., 1994; Cohen and Kozin, 2001; Garcia-López et al., 2001; Kendall et al., 2005; Krakauer et al., 1994; Shindle et al., 2007; Vance et al., 2005; Watson et al., 1999; Wyrick et al., 1995). However, there is no consensus on the best technique.

We present our experience with a new method for four-corner fusion using the Quad Memory Staple (QMS), which provides stable internal fixation by compressing the carpal bones and allows a short immobilisation time.

METHODS

All adult patients with degenerative arthrosis or post-traumatic radioscaphoid arthrosis who underwent a combined scaphoid excision and arthrodesis of the capitate, lunate, hamate and triquetrum using the QMS between January 2001 and May 2004 were analysed retrospectively with a minimum follow-up of 18 months. All operations were performed by one surgeon and were carried out at our University Hospital.

The authors declare that they have no financial or other interest in the product or the firm mentioned in the paper (Quad Memory Staple (QMS), Bio Recherches Innovations (Le Mas Des Trois Dauphins), Le Luc en Provence, France).

The QMS (Bio Recherches Innovations (Le Luc en Provence, France)) was used for all of the carpal fusions in this study. This four-pronged memory staple is quadrilateral and made of a proprietary biocompatible nickel–titanium shape-memory alloy that has the ability to transit between a low-temperature martensitic phase (open form) and a high-temperature austenitic phase (closed form). The transition takes place at a temperature that depends on the composition of the alloy; for the QMS it is 50 °C. The staples are manufactured at high temperature in closed form. After lowering the temperature below the transition temperature, the staple reverts to an open form. During surgery, the staple is reheated above transition temperature, causing it to revert to the closed form and compress the bone fragments.

The operation technique is straightforward (Fig 1). After dorsal wrist exposure according to Berger et al. (1995), a scaphoidectomy is performed, and the cartilage and cortex of the joint surfaces between the carpal bones are removed. The correct alignment of the lunate is then secured by temporary fixation to the radius with a K-wire. The carpal bones are held in the correct position. A jig (Fig 2) is placed in the centre of the carpal bones so that the holes are at an equal distance to the former cortex of the bones and holes are drilled in the lunate, capitate, triquetrum and hamate. The holes correspond to the legs of the staple (Fig 2); the staple is placed with one leg in each bone. The legs of the staple are of standard length and there is no need to shorten them, i.e., the legs will not protrude through the volar cortex of the carpal bones. The excised scaphoid is morcellised and placed between the carpal bones as

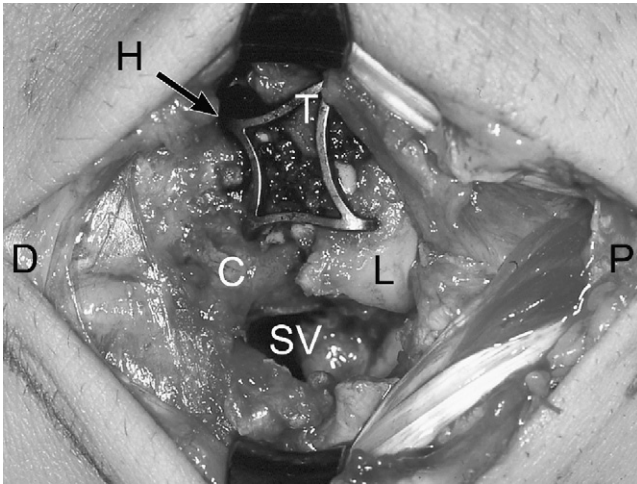


Fig 1 During surgery D = distal, P = proximal, L = lunate, C = capitate, T = triquetrum, H = hamate and SV = scaphoid void.




Fig 2 The jig and the compressed staple (closed form).

graft. The monopolar diathermy equipment is used to heat the staple above 50 °C. A few seconds of contact on all sides of the staple is enough to make the staple contract, and the contraction is clearly visible. After a few seconds, the contraction of the staple lessens and then ceases as the staple is transformed into its closed form, where it remains.

The wrist is immobilised in a below-elbow cast in the neutral position. During the course of this study, we shortened the postoperative immobilisation time from 6 to 4 weeks. Mobilisation is started immediately after cast removal under the supervision of a hand therapist, with a removable splint used if necessary.

The hand function of the patients was assessed by hand therapists pre-operatively and postoperatively. Range of motion of both wrists was measured in extension, flexion, ulnar deviation and radial deviation.

Grip strength was measured in kilograms with the Jamar dynamometer in position 2. Pain was evaluated by the patients using a visual analogue scale (VAS) on a scale from 0 (no pain) to 100 (unbearable pain). Limitations in daily life were evaluated by the official Dutch Language Version of the Disabilities of Arm, Shoulder, and Hand (DASH) questionnaire. The questionnaire comprises 30 questions concerning symptoms and restriction of various physical activities. Depending on their abilities, patients can assign scores from 1 to 5 per question. Subsequently, the total score was transformed to a score ranging from 0 (no limitations in daily functioning) to 100 (severe disabilities). A radiograph was taken after cast removal, e.g., 4 to 6 weeks after surgery, and regularly thereafter until consolidation was confirmed by the surgeon. Consolidation was defined as disappearance of the gaps between the carpal bones (Fig 3). At each visit, the patient was examined for complications such as infection, delayed union and non-union, and the findings recorded in the case notes.

RESULTS

Between January 2001 and May 2004, 18 patients underwent four-corner arthrodesis. Three patients were lost to follow-up, one was excluded because she had fractured the consolidated arthrodesis and another was excluded because of Ehlers–Danlos syndrome. Pre-operative data were missing for four patients, resulting in nine complete pre-operative and postoperative data sets.

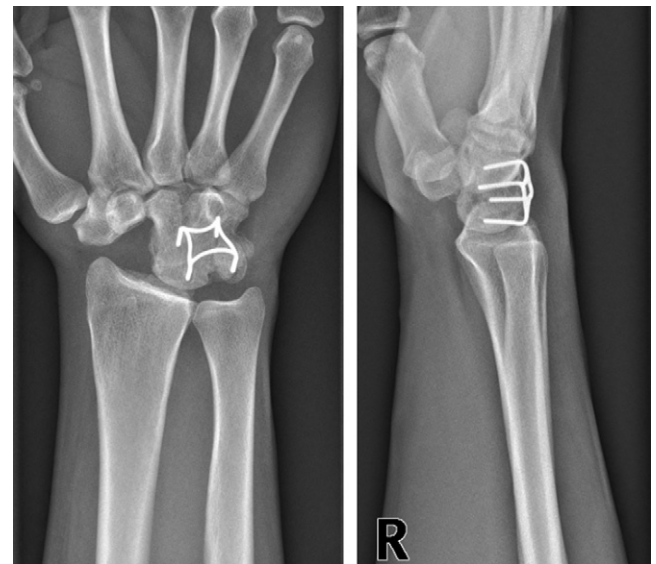

Fig 3 Postoperative radiograph: In this lateral view the staple appears proximally. A possible disadvantage of the technique is dorsal impingement of the staple against the radius when the wrist is in full extension.

Four women and five men with an average age at surgery of 42 years (range 25–76 years) were available for follow-up at a mean of 44 months (range 18–86 months). Five arthrodeses were in the dominant wrist.

The mean extension was 50° before and 32° after surgery. Flexion reduced from a mean of 62° to 31°. The mean radial deviation was 9° pre-operatively and 15° postoperatively. Ulnar deviation was 24° before surgery and 20° after surgery. Mean grip strength was 28 kg pre-operatively and 26 kg postoperatively.

The mean VAS was 41 before surgery and 23 after surgery. The mean DASH score improved from 24 before surgery to 20 after surgery.

Radiographic evidence of fusion was seen in four patients at 8 weeks, in five patients at 15 weeks and in eight patients at 22 weeks. Earliest consolidation was seen at 4.5 weeks and by 32 weeks all four-corner fusions were consolidated.

No non-unions, haematomas or wound infections were recorded. In three patients the staple was removed to relieve pain at the extreme of extension. A loose staple was removed in another patient.

DISCUSSION

Four-corner fusion with scaphoid excision has proved to be an effective solution for chronic wrist pain in degenerative conditions where the radiolunate joint is healthy, while at the same time preserving some wrist motion (Ashmead et al., 1994; Cohen and Kozin, 2001; Krakauer et al., 1994; Tomaino et al., 1994; Watson et al., 1999; Wyrick et al., 1995). However, a consensus on the best method of fixation (K-wires, headless screws, dorsal circular plate) has not been reached, and new techniques and materials are frequently introduced (Kendall et al., 2005; Shindle et al., 2007; Vance et al., 2005).

We believe the QMS staple method of fusion has two major advantages over traditional techniques. Firstly, placement of the staple on the dorsal surface of the carpal bones, where it is covered by joint capsule, tendons and skin, avoids the risk of infection inherent in K-wire fixation and allows rehabilitation. Removal is

performed only when this is the patient's explicit wish, or when the staple limits extension of the wrist or causes pain due to impingement.

The second advantage over the traditional fixation methods is the compression provided by the staple (Kendall et al., 2005; Shindle et al., 2007; Vance et al., 2005), which reduces or eliminates the gap between the bone fragments. This compression may expedite healing between the carpal bones (Musialek et al., 1998).

In most studies (Cohen and Kozin, 2001; Goldfarb et al., 2004; Sauerbier et al., 2000; Wyrick et al., 1995), the immobilisation period was between 6 and 10 weeks. Only Garcia-López et al. (2001) described a shorter (3 weeks) immobilisation period than ours. Increasing confidence with the security of QMS fixation led us to shorten the postoperative immobilisation time from 6 to 4 weeks. At 4 weeks a removable splint is worn and passive exercises are performed for the next 2 weeks. Thereafter, mobilisation is increased under the supervision of hand therapists.

Despite the short immobilisation period, fusion was achieved in all nine cases. Our study is too small to give confidence in a high fusion rate, but these results are encouraging when considered against other reports in the literature in which K-wires, staples and multiple Herbert screws were used. Watson et al. (1999) showed 3% non-union in 252 patients treated with K-wires. However, Krakauer et al. (1994) described two painful non-unions in 23 patients (with K-wires, multiple Herbert screws and staples). In a group of 19 patients all treated with K-wires (Cohen and Kozin, 2001), one patient had a non-union. Three of 17 patients fixed with K-wires and staples had non-union (Wyrick et al., 1995).

Pain and disability scores improved but the improvement was not statistically significant in this small study.

Four studies (Garcia-López et al., 2001; Goldfarb et al., 2004; Krakauer et al., 1994; Tomaino et al., 1994) have confirmed the loss of motion that is inherent in four-corner arthrodesis, as was found in our patients. Grip strength was measured in three studies and an improvement of 2, 12 and 12 kg, respectively, was found (Garcia-López et al., 2001; Goldfarb et al., 2004; Tomaino et al., 1994). In our study the grip strength was 28 kg before and 26 kg after surgery. However, the

Table 1—Summary of reported motion and strength

Study	No. of cases	Follow-up (months)	Extension	Flexion	Radial deviation	Ulnar deviation	Mean grip strength (kg)
Garcia-López et al. (2001)	16	38	34/22	21/27	10/12	22/20	20/22
Tomaino et al. (1994)	9	48	38/22	43/30	10/5	23/13	25/37
Goldfarb et al. (2004)	8	35	70/40	75/35	9/9	35/25	20/32
Krakauer et al. (1994)	23	41	40/27	33/27	7/14	23/26	./.
Amerongen (2008)	9	44	50/32	62/31	9/15	24/20	28/26

Mean range of motion expressed as pre-operative/postoperative.

pre-operative grip strength was relatively high in our population and postoperatively our patients reached a grip strength that is comparable to figures in the literature (Table 1).

The possible disadvantage of the technique is dorsal impingement of the staple against the radius in full extension. Impingement is not seen during the initial rehabilitation, but once the patients have resumed their daily routine, pain could occur if the wrist is fully extended. To minimise the risk of impingement, it is important to place the staple distally in the carpal bones, particularly in the lunate.

On the basis of this small study, which showed union in every case and satisfactory results for movement and strength, we believe that shape-memory alloy staple fixation is a promising technique that merits further study in four-corner arthrodesis.

Acknowledgements

We thank M. Peters and N. Brongers, hand therapists at the University Hospital Utrecht, the Netherlands, for their help in hand function assessment.

References

- Ashmead D, Watson HK, Damon C, Herber S, Paly W. Scapholunate advanced collapse wrist salvage. *J Hand Surg Am.* 1994, 19: 741–50.
- Berger RA, Bishop AT, Bettinger PC. New dorsal capsulotomy for the surgical exposure of the wrist. *Ann Plast Surg.* 1995, 35: 54–59.
- Cohen MS, Kozin SH. Degenerative arthritis of the wrist: proximal row carpectomy versus scaphoid excision and four-corner arthrodesis. *J Hand Surg Am.* 2001, 26: 94–104.
- García-López A, Perez-Ubeda MJ, Marco F, Molina M, López-Duran L. A modified technique of four-bone fusion for advanced carpal collapse (SLAC/SNAC wrist). *J Hand Surg Eur.* 2001, 26: 352–54.
- Goldfarb CA, Stern PJ, Kiefhaber TR. Palmar midcarpal instability: the results of treatment with 4-corner arthrodesis. *J Hand Surg Am.* 2004, 29: 258–63.
- Kendall CB, Brown TR, Millon SJ, Rudisill LE, Sanders JL, Tanner SL. Results of four-corner arthrodesis using dorsal circular plate fixation. *J Hand Surg Am.* 2005, 30: 903–07.
- Krakauer JD, Bishop AT, Cooney WP. Surgical treatment of scapholunate advanced collapse. *J Hand Surg Am.* 1994, 19: 751–59.
- Musialek J, Filip P, Nieslanik J. Titanium-nickel shape memory clamps in small bone surgery. *Arch Orthop Trauma Surg.* 1998, 117: 341–344.
- Sauerbier M, Tränkle M, Linsner G, Bickert B, Germann G. Midcarpal arthrodesis with complete scaphoid excision and interposition bone graft in the treatment of advanced carpal collapse (SNAC/SLAC wrist): operative technique and outcome assessment. *J Hand Surg Eur.* 2000, 25: 341–45.
- Shindle MK, Burton KJ, Weiland AJ, Domb BG, Wolfe SW. Complications of circular plate fixation for four-corner arthrodesis. *J Hand Surg Eur.* 2007, 32: 50–53.
- Tomaino MM, Miller RJ, Cole I, Burton RI. Scapholunate advanced collapse wrist: proximal row carpectomy or limited wrist arthrodesis with scaphoid excision? *J Hand Surg Am.* 1994, 19: 134–42.
- Vance MC, Hernandez JD, DiDonna ML, Stern PJ. Complications and outcome of four-corner arthrodesis: circular plate fixation versus traditional techniques. *J Hand Surg Eur.* 2005, 30: 1122–27.
- Watson HK, Weinzweig J, Guidera PM, Zeppieri J, Ashmead D. One thousand intercarpal arthrodeses. *J Hand Surg Am.* 1999, 24: 307–15.
- Wyrick JD, Stern PJ, Kiefhaber TR. Motion-preserving procedures in the treatment of scapholunate advanced collapse wrist: proximal row carpectomy versus four-corner arthrodesis. *J Hand Surg Am.* 1995, 20: 965–70.

Received: 25 August 2005

Accepted after revision: 15 May 2008

A.H. Schuurman, Department of Plastic and Reconstructive and Hand Surgery, University of Utrecht, G04 122, PO Box 85500, 3508 GA Utrecht, The Netherlands. Tel.: +31 88 7556955; fax: +31 88 7556307.

E-mail: a.schuurman@umcutrecht.nl

doi:10.1177/1753193408094444 available online at <http://jhs.sagepub.com>